

New Modalities for the Treatment of Traumatic Arthrosis of the Proximal Interphalangeal Joint: Comparative Study between Perichondrial and Chondro-Perichondrial Graft

AHMAD S. EL-BADAWI, M.D.; AHMAD ALI, M.D.; MAGDI SHERIF, M.D.;
AHMAD M. ABO-ELWAFI, M.D. and IKRAM I. SAFE, M.D.

The Department of Plastic and Reconstructive Surgery, Ain Shams University, Cairo, Egypt.

ABSTRACT

The proximal interphalangeal joint does a major role in hand function. Traumatic arthrosis of the joint adversely affects the function of the hand. Many techniques were tried to restore function of the joint. Most of these techniques have pitfall in term of limited active range of motion restored. This study is designed to treat post-traumatic P.I.P joint arthrosis by the incorporation of free chondroperichondrial (group I) and Perichondrial (group II) grafts. They were harvested and fixed to the damaged articular surfaces of the P.I.P joint in an attempt to generate new-cartilage. Twenty patients were studied in two groups (each group was ten patients). Postoperative evaluation was based on clinical restoration of active range of motion and Radiological evidence of new joint formation. Our study proved that free chondro-perichondrial and perichondrial grafts have the ability to create new joint space with functioning cartilaginous articular surfaces permitting free active movement of the P.I.P joint. There was no statistically significant difference in the results between the two methods. The use of either free perichondrial or chondro-perichondrial graft is a good option to restore the function of the P.I.P joint of the hand.

INTRODUCTION

The proximal interphalangeal joint (P.I.P) plays a major role in hand function. This joint has the greatest range of motion of any finger joints [1]. Despite this, the joint is poorly protected during hand activities, which partially explains its frequent injury [2]. The proximal interphalangeal joint is a Trochlear joint. The shape of the articular surfaces and the arrangement of the connecting structures facilitate sagittal flexion-extension to the utmost [3]. Lateral movements and rotation are effectively prevented whatever the position of the finger. This joint is therefore free to move in one plane only. The articular surfaces consist of the head of the proximal phalanx (P1) and the base of the middle phalanx (P2). The base glides on the head by the action of the flexor and extensor tendons [4].

The joint capsule is thin, loose and supple. Its length can be doubled during finger flexion and extension. It is reinforced anteriorly by the volar plate and on both sides by the collateral ligaments. But Dorsally It is lax and supple and is related to the extensor expansion [3]. The articular surfaces are covered by 1-5 mm dense white connective tissue called hyaline articular cartilage. Owing to its histological structure, this tissue allowing movement of the opposing joint surfaces with minimal friction and wear [5].

The adult articular cartilage lacks the capacity to repair structural damage resulting from injury or disease [6]. The native repair response to such injuries typically results in a Joint surface that is deficient in its histological, biochemical and biomechanical properties [7,8]. So, damage of the articular cartilage is a common problem and can lead to premature arthritis [9].

Intra-articular fracture of the P.I.P joint is the most common cause of development of post-traumatic arthritis with functional disability due to pain and loss of motion [10]. Post-traumatic arthritis of the P.I.P joint of the digits has long been a challenge to the surgeons. It usually occurs in young, active manual workers who need a mobile, painless and stable joint [11]. The challenge after trauma is the restoration of smooth articular cartilage and the congruency of the articular surfaces to maintain adequate function [12].

For many years and still for some authors, Arthrodesis was a reasonable treatment [13-16]. Arthrodesis results in a stable and painless joint but without mobility. Furthermore, arthrodesis was associated with delayed healing [11].

The goal of P.I.P joint arthroplasty is to provide a stable, painless joint with a useful range of motion and acceptable appearance [17]. Many techniques have been used for P.I.P joint reconstruction. These include resection arthroplasty [17,18], interposition arthroplasty [19], prosthetic arthroplasty [20] and vascularized joint transfer [2]. None have been universally successful.

Restoring cartilaginous articular surfaces have been suggested through either perichondrial arthroplasty [21-24] or perichondrio-costochondrial arthroplasty [25].

These two techniques are based on the chondrogenic potential of the perichondrium that was identified as early as 1877 by Tizzoni. Johansson and Enghvist, [26] have studied the potential of perichondrial grafts to form new cartilage. They concluded that free perichondrial grafts are able to generate viable chondroid tissue.

This study is designed to evaluate the clinical results of treatment of post-traumatic damaged articular surfaces of the P.I.P. joint by either chondroperichondrial or perichondrial arthroplasty.

PATIENTS AND METHODS

This study was conducted in the Plastic Surgery Department, Ain Shams University and in Nasr City Insurance Hospital in the period between August, 1998 and August 2000.

The study included twenty post-traumatic damaged P.I.P joints of the fingers in nineteen patients. All patients were assessed pre-operatively as regards age, sex, occupation, hand dominance, finger affected, time since trauma and the presence or absence of pain. The age of the patients varied from 22 to 52 year with an average of 35 years. Nineteen patients were males, right handed and manual workers. One patient was female nurse, left handed. The index finger was affected in one patient, the middle finger in five patients, the ring finger in two patients and the little finger in two patients.

All patients were examined as regards the extent of skin and soft tissue scarring, the presence or absence of associated tendon injuries, passive and active range of motion and radiological evaluation of the joint. All patients were operated upon under general anesthesia and pneumatic tourniquet with prophylactic antibiotic in the form of ceftazidime, one gram given intravenous intraoperative and 1 gm/day for one week postoperative. The approach was determined according to the site and extent of previous scarring and associated tendon injuries.

The approach was volar in five fingers (25%) and dorsal in fifteen fingers (75%).

Joints were divided into two groups:

Group I: (chondro-perichondrial arthroplasty):

The affected finger was in the dominant hand in five patients and in non dominant hand in five patients (Table 1). Five patients presented before one year and five patients presented one year after trauma.

Table (1): Frequency and percentage of finger affected in group (I).

Finger's affected	Lt. Index	Rt. Index	Lt. Middle	Rt. Middle	Lt. Ring	Rt. Ring	Lt. Little	Rt. Little
Frequency	1		2	3	1	1	2	
%	10		20	30	10	10	20	

The approach of exposure was volar in three patients (30%) and dorsal in seven patients (70%). In five patients (50%) there was an associated extensor tendon injury. Flexor tendon injuries were found in two patients (20%). Both tendon injuries were found in two patients (20%) and in one patient there was no tendon injury. The preoperative X-Ray findings showed an absent joint space in four patients (40%) and narrow irregular joint space was found in six patients (60%).

The joints were grafted with free perichondrio-chondral grafts (perichondrium incorporating a thin layer of cartilage about 0.5-1 mm thick) harvested from the lower ribs (6th and 7th). The graft was fixed using 6/0 proline suture passed through a predrilled holes in the bone ensuring that the cartilaginous surface was directed toward the joint space.

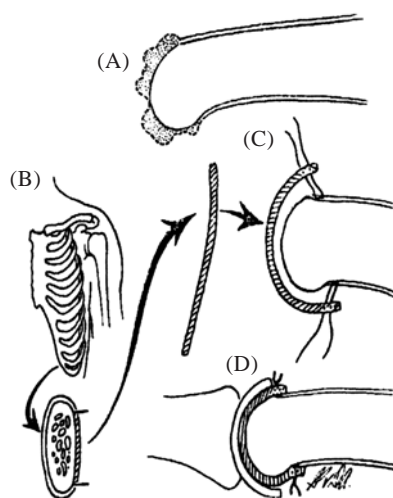


Fig. (1): Technique of perichondrial arthroplasty. A- Arthritic portion of joint is excised. B- Perichondrium is harvested from a single rib. C- The joint is resurfaced with the perichondrium. D- The perichondrium is sutured in place. A silicone sheet is interposed between the joint surfaces. (Quoted from Ellis and Tsai, 1989 [17]).

All patients required resurfacing of both joint surfaces. Simultaneous tenolysis was done with the procedure. Patients with both flexor and extensor tendon injuries required 2nd stage of tenolysis.

Group II: (perichondrial arthroplasty):

All patients were right handed, male manual workers. The frequency of the affected fingers was the index in three patients (30%), the middle in two patients (20%), the ring in four patients (40%) and the little finger in one patient (10%) (Table 2).

All fingers were in the non dominant hand. Five patients presented before one year and five patients presented after one year following trauma.

Table (2): Frequency of the affected finger in group (II).

Finger's affected	Lt. Index	Lt. Middle	Lt. Ring	Lt. Little
Frequency	3 (30%)	2 (20%)	4 (40%)	1 (10%)

The approach of exposure was volar in two patients (20%) and dorsal in eight patients (80%). There were an associated extensor tendon injury in two patients (20%), flexor tendon injury in two patients (20%), both tendons injuries in two patients (20%) and no tendon injuries in four patients (40%).

The preoperative X-ray revealed absent joint space in five patients (50%) and narrow irregular joint space in five patients (50%). The joints were grafted with perichondrial graft harvested from the lower ribs (6th and 7th). Simultaneous tenolysis was performed with the procedure. Patients with both tendons injury required 2nd stage of tenolysis three months after arthroplasty.

The desired perichondrio-costochondral graft is harvested from the costal margin. A perichondrial graft is taken with a thin layer of subjacent hyaline cartilage (0.5-1mm) thick (Fig. 2). The graft is then sutured over the exposed subchondral cancellous bone using 6/0 praline through pre-drilled holes ensuring that the cartilagenous surface is directed into the joint space.

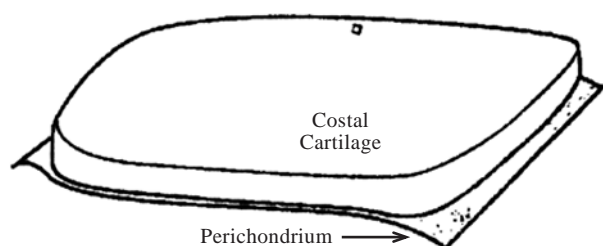


Fig. (2): The perichondrium is harvested with an underlying layer of costal cartilage 0.5-1 mm in depth. (Quoted from Katsaros et al., 1995 [25]).

All patients required resurfacing of both joint surfaces. A silicone rubber spacer (sheet) 1 mm in thickness was interposed between the two surfaces. This silicone sheet was removed 3 months postoperatively.

The patients of both groups were splinted for two weeks followed by active and passive exercises for 2 months. Postoperatively, all patients in both groups were evaluated both clinically and radiological.

Postoperative care:

Immobilization for two weeks in position of full extension. Gentle active and active assisted range of motion is initiated during the 3rd week.

Clinical assessment:

All patients were clinically evaluated for the active and passive range of motion (ROM), the presence or absence of pain, patient satisfaction and the presence of complications. The results were graded as good, fair and poor according to the presence or absence of pain and patient satisfaction [27] and postoperative active ROM [28] (Table 3).

Table (3): Criteria described by Seradge et al., 1984 and Swanson et al., 1985 for postoperative evaluation of the patients [27,28].

	Pain	ROM	Pt. Satisfaction
Good	Absent	$\geq 40^\circ$	Satisfied
Fair	Occasional	$15-40^\circ$	Satisfied
Poor	Present at work	$\leq 15^\circ$	Unsatisfied

Radiological evaluation:

Joint space and congruency of the articular surfaces were radiological evaluated.

RESULTS

Group I: (Chondro-perichondrial arthroplasty):

The active R.O.M. increased in all patients after the operation. There was a highly significant difference ($p = 0.00$) between the preoperative mean active R.O.M. (8.9 ± 7.8) and postoperative mean active R.O.M. at three months (31.7 ± 6.6) and six months (39.5 ± 12.1) (Table 4). After six months there was no increase in the active R.O.M. in the eight patients who continued their follow up to 18 months (Table 4).

Table (4): Active R.O.M. in group (I).

No.	Pre-operative	1 m	3 ms	6 ms	2 nd procedure
1	10	25	35	70	Revision Arthrodesis
2	15	20	25	40	
3	20	25	35	35	
4	0	20	25	30	
5	15	25	40	40	Arthrolysis Arthrodesis
6	5	25	40	45	
7	15	25	30	35	
8	0	25	30	35	
9	0	25	30	40	
10	0	15	20	25	
8.9±7.8 22.5±3.5 31.7±6.6 39.5±12.1					

Also, there was a statistically highly significant difference ($p = 0.00$) between the preoperative passive R.O.M. (14.5 ± 16.7) and postoperative passive R.O.M. at three months (61.5 ± 3.94) and at six months (70 ± 12.2). After six months there was no increase in the passive R.O.M. in the eight patients who continued their follow up to 18 months (Table 5).

Table (5): Passive R.O.M. in group (I).

No.	Pre-operative	1 m	3 ms	6 ms	2 nd procedure
1	20	50	70	90	Revision Arthrodesis
2	20	40	60	60	
3	20	35	50	60	
4	0	40	70	70	
5	30	50	60	75	Arthrolysis Arthrodesis
6	5	40	75	80	
7	50	60	60	75	
8	0	30	40	50	
9	0	40	80	80	
10	0	30	50	60	
14.5±16.7 41.5±9.4 61.5±3.94 70±12.2					

The mean postoperative passive ROM was (70 ± 12.2) while the mean postoperative active ROM was (39.5 ± 12.1) showing statistically highly significant difference ($p = 0.00$).

Pain relief was achieved in nine patients (90%) and was persistent in only one patient due to volar subluxation of proximal phalanx. This patient was subjected to an arthrodesis of P.I.P joint one year after arthroplasty.

Eight patients (80%) were satisfied from the procedure as regards the use and appearance of the finger. Two patients (20%) were unsatisfied from the operation because they developed volar subluxation of proximal phalanx three months after arthroplasty and an arthrodesis was performed for them.

Postoperative functional categorization of this group based on pain relief, patient satisfaction and active ROM was done. The results considered good in five patients (50%), fair in three patients (30%) and two patients (20%) had poor results.

The postoperative X-Rays revealed that joint space was reconstructed and maintained in seven patients (70%), narrow and irregular in one patient who subjected to revision three months post-arthroplasty. There was volar subluxation in two patients and they had an arthrodesis of P.I.P joint later on.

The effect of associated tendon injuries on late active ROM:

The mean postoperative active ROM in joints without associated tendon injuries was 70° . In joints with extensor tendon injuries, ROM was $39^\circ \pm 4.1$. In joints associated with flexor tendon injuries, it was $37^\circ \pm 3.5$ in joints associated with both tendon injuries, it was $37^\circ \pm 3.5$. In comparison, there was a highly significant difference between cases with and without associated tendon injuries. Also, there was a statistically significant difference between cases with one tendon and cases with both tendon injuries (Table 6).

Table (6): Effect of associated tendon injuries on postoperative active and passive ROM in group (I).

	No. of cases	Active ROM	Passive ROM
No tendon injuries	1	70°	90°
Ext. tendon injuries	5	39°	69°
Flexor tendon injuries	2	37°	76°
Both tendon injuries	2	27°	65°

There was no statistically significant difference in the mean postoperative passive ROM in cases without associated tendon injuries 90° and cases with associated tendon injuries (extensor tendon injuries $69^\circ \pm 13.4$, flexor tendon injuries $67^\circ \pm 10.7$ and both tendon injuries ($65^\circ \pm 7$).

The mean active ROM in patients with an affected finger in the dominant hand was 40 ± 3.5 , while in those with an affected finger in the non dominant hand was 42 ± 17.1 , showing no statistical difference.

The number of patients presented one year after trauma was five with a mean ROM $42^\circ \pm 16.8$, while those presented before one year following trauma was five with a mean ROM $37^\circ \pm 5.7$, showing no statistical difference ($p = 0.51$). Patients with

limited preoperative ROM and had narrow joint space (no = 6) showed statistically significant improvement in the mean active ROM ($46.3^{\circ} \pm 10$) than those with no ROM and had ankylosed joints (N = 4) who achieved a mean active ROM of $32.5^{\circ} \pm 6.4$ preoperative and postoperative clinical results are shown in Figs. (3-15).

Postoperative complications in group (I):

Two patients developed volar subluxation of PI. These two patients were subjected to capsulotomy three months before arthroplasty. An arthrodies of the P.I.P joint in position of function was done for both patients one year after arthroplasty to correct the subluxation.

One patient required total revision (the joint space was narrow and irregular on X-Ray) three months after the primary procedure. Following revision there was an improvement in the active ROM from 25° to 40° while there was no change in the passive ROM.

One patient required arthrolisis two months after arthroplasty. It improved the active ROM from 25° to 45° and the passive ROM from 40° to 75° .

Group II: Perichondrial arthroplasty:

The active ROM increased in all patients after the operation. There was a highly significant difference ($p = 0.00$) between the preoperative mean active ROM (5 ± 5.8) and postoperative mean active ROM at three months (27 ± 6.3) and at six months (36 ± 6.6). There was progressive increase in the mean active ROM for 6 months after the operation (one month 24.5 ± 6.9 , three months 27 ± 6.3 and six month 36 ± 6.6) (Table 7) after six months there was no increase in the active ROM in the eight patients who continued their follow up to 18 months.

There was also a statistically highly significant difference ($p = 0.00$) between the preoperative passive R.O.M. (16 ± 19.1) and postoperative passive ROM at three months (51.5 ± 10.5) and at six months (64 ± 9.7) (Table 8). After six months there was no increase in the passive R.O.M. in patients who continued their follow up.

The mean postoperative passive ROM was 64 ± 9.7 while the mean postoperative active ROM was 36 ± 6.6 showing statistically highly significant difference ($p = 0.00$).

Pain relief was achieved in eight joints (80%) and was persistent with light work in two patients (20%). One of them developed partial ankylosis

(revealed on X-Ray) and was treated with volar plate arthroplasty three months after the primary operation. Follow up of this patient showed pain relief but there was no improvement in the ROM.

The other one required total revision after three months with improved ROM from 20° to 30° and from 60° to 70° active and passive ROM respectively.

Eight patients (80%) were satisfied with the overall results of their surgery while two patients (20%) were unsatisfied from procedure.

Postoperative functional categorization of this group based on pain relief, patient satisfaction and active R.O.M. was done five patients (50%) had good results, three patients (30%) had fair results and two patients (20%) had poor results.

Radiological adequate joint space was reconstructed in eight joints (80%) while there was a narrow irregular joint space in two joints (20%). One of them was subjected to volar plate arthroplasty and the other patient had total revision.

The effect of associated tendon injuries on late active ROM:

The mean postoperative active ROM in the cases without associated tendon injuries was 38 ± 6.3 , with extensor tendon injury was 35 ± 7.07 , with flexor tendon injury was 37 ± 10.6 and in cases with both tendon injuries was 30. In comparison, there was a statistically significant difference between cases without tendon injuries and cases with associated flexor and extensor tendons injuries while there was a statistically insignificant difference between cases with one tendon injury and cases with both tendon injuries.

There was no statistically significant difference in the mean postoperative passive ROM in cases without associated tendon injuries (67 ± 9.6) and cases with associated tendon injuries (extensor tendon 70 ± 14.1 , flexor tendon 70 ± 14.1 and both tendons 60 ± 14.1) (Table 9).

The mean postoperative active ROM of patients presented one year after trauma was 33.8 ± 7.5 and those presented before one year following trauma was 38.8 ± 6.3 , showing no statistical difference ($p = 0.2$). Patients with limited preoperative ROM and narrow joint space (six patients) showed a statistically significant improvement in the mean active ROM 40 ± 5 . Preoperative and postoperative clinical and radiological results are shown in Figs. (16-20).



Fig. (3): A preoperative photograph for patient with P.T. stiff P.I.P. joint of right middle finger (ROM = 15°).

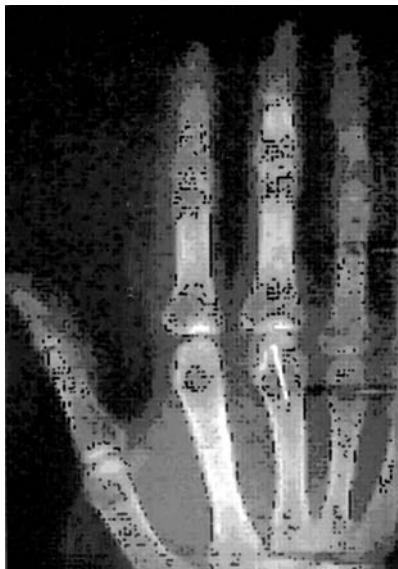

Fig. (4): A preoperative X-ray for the same patient showing that the joint space was narrow and irregular.

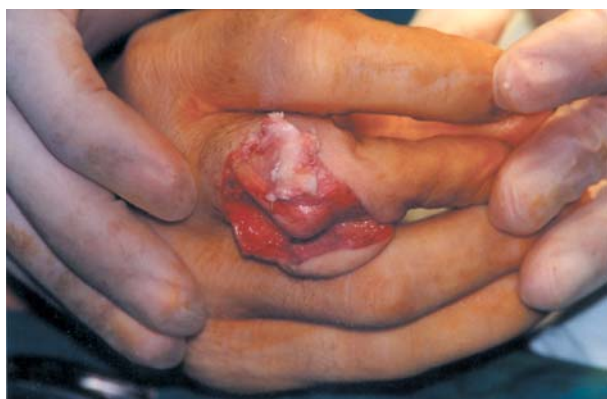

Fig. (5): Intraoperative view for the same patient showing that the articular cartilage is dull and grey in color with areas of cartilage loss (arthritic changes).

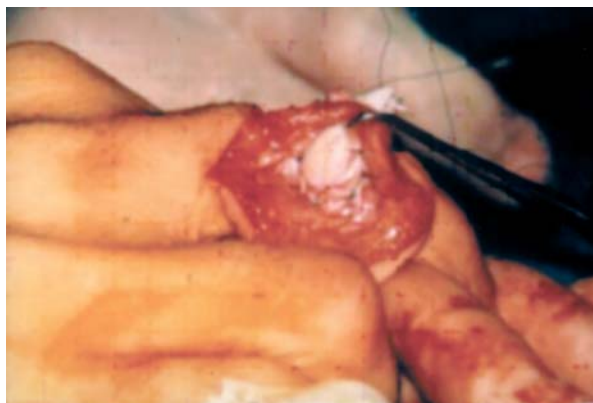

Fig. (6): Intraoperative view after debridement of the damaged articular cartilage and application of perichondrio-costochondral grafts for both articular surfaces.

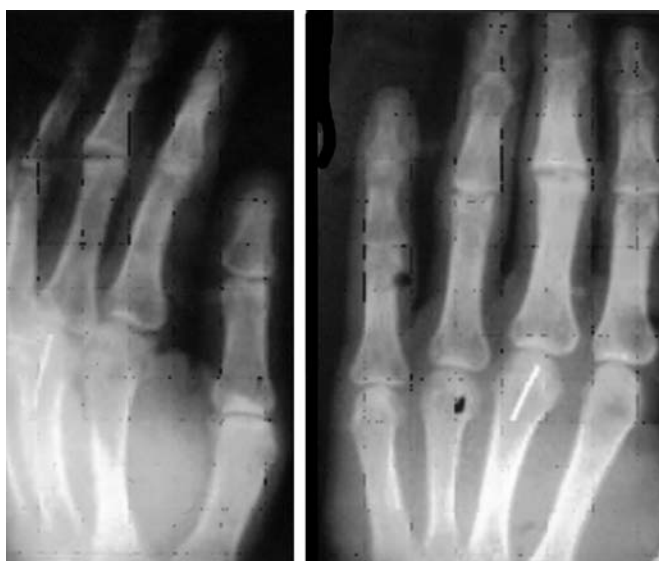


Fig. (7): Postoperative X-ray for the same patient showing that the joint space has been reconstructed (3 months postoperative).

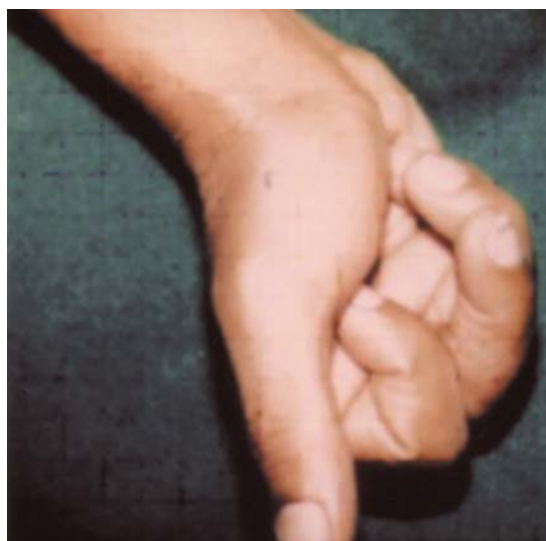

Fig. (8): Postoperative photograph for the same patient showing the degree of improvement in the ROM (40°) (6 months postoperative).

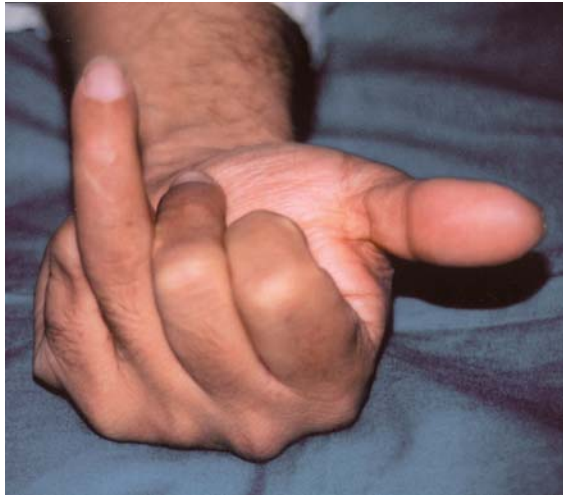

Fig. (9): A preoperative photograph for patient with P.T. stiff PIP joint of left ring finger (ROM = 0°).

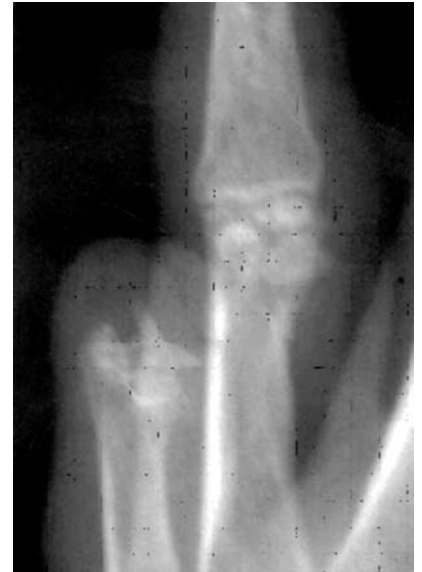

Fig. (10): A preoperative X-ray for the same patient showing narrow irregular joint space with old comminuted fracture of the head of PI.

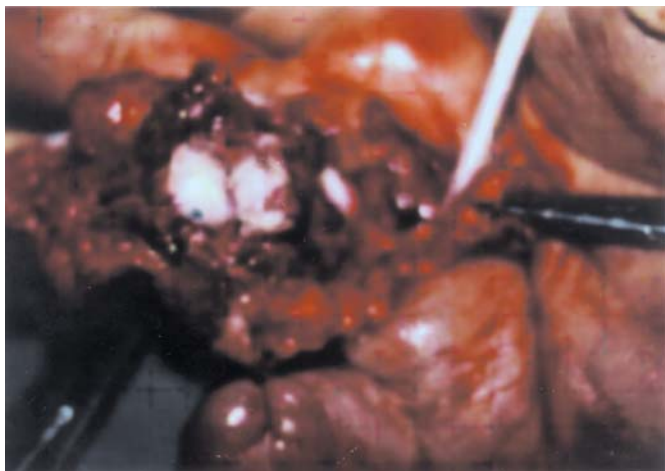


Fig. (11): Intraoperative view of volar approach for perichondrocostochondral arthroplasty with resurfacing of both joint surfaces (there was extensive adhesion of flexor tendons which were subjected to 2 stages tendon reconstruction using silicone rod).

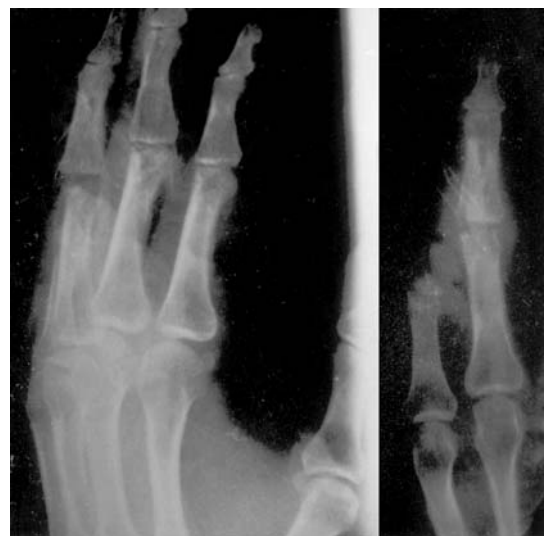

Fig. (12): Postoperative X-ray for the same patient showing that the joint space has been reconstructed (3 months postoperative).

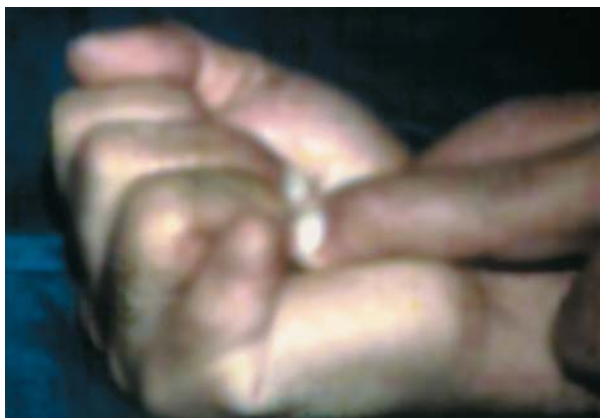

Fig. (13): Postoperative photograph for the same patient showing the passive ROM 3 months postoperative = 80°.

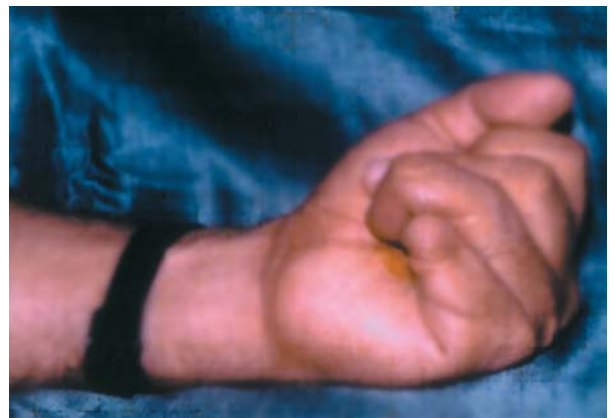

Fig. (14): Postoperative photograph for the same patient showing the active ROM. 1 year post operative = 40°.

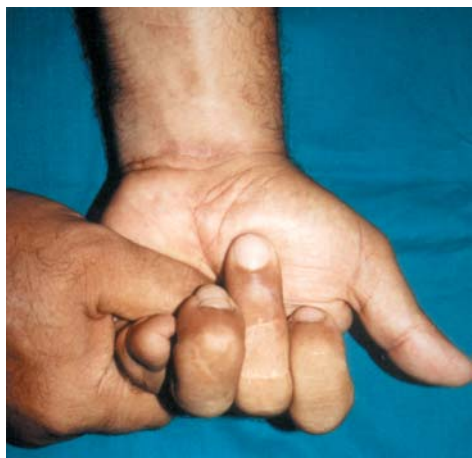

Fig. (15): Postoperative photograph for the same patient showing that the ROM has increased (60°) after the flexor tendon has been maintained adjacent the bone (as there was bowstringing at level of A2 pulley).

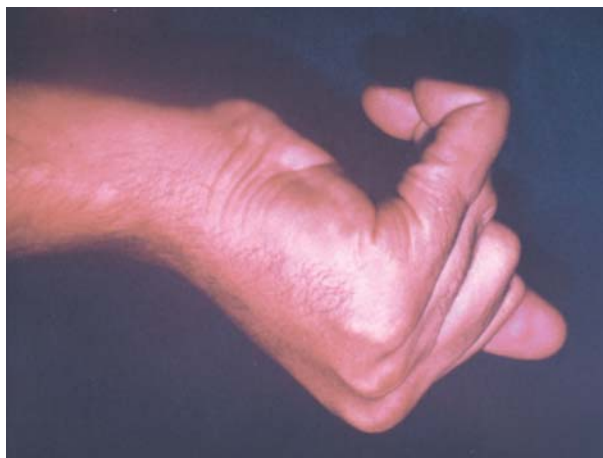

Fig. (16): Preoperative photograph for patient with P.T stiff PIP joints of both left ring and little fingers (ROM ring = 15° little = 0°).

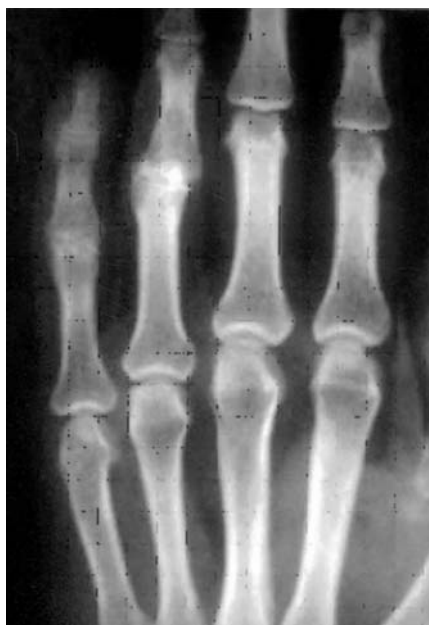

Fig. (17): Preoperative X-ray for the same patient showing obliteration of both joint spaces.

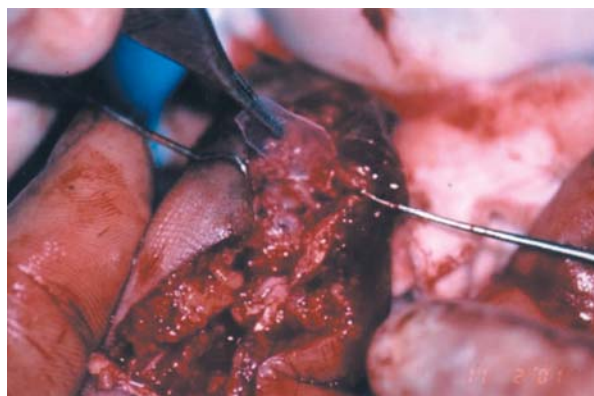


Fig. (18): Intraoperative view at time of silastic sheet removal showing the silastic sheet and both articular surfaces.

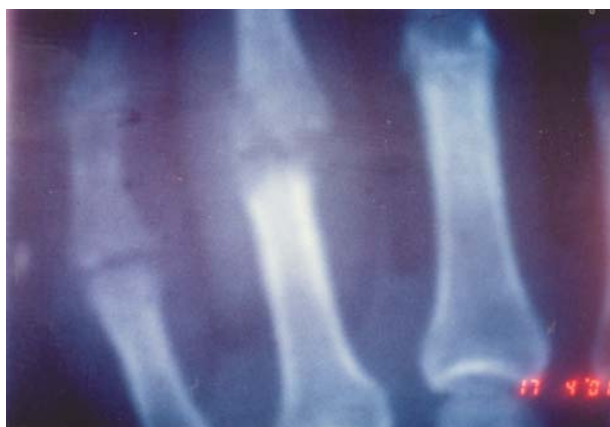

Fig. (19): Postoperative X-ray for the same patient showing that the joint spaces have been reconstructed.

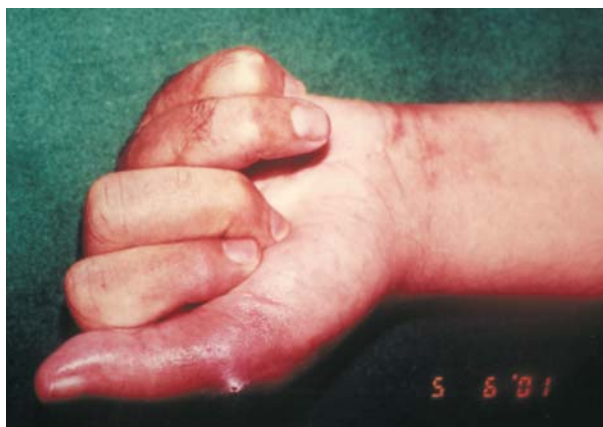

Fig. (20): Postoperative photograph for the same patient showing the degree of improvement in the ROM 6 months after the operation (ring = 30° little = 35°).

Table (7): Active ROM in group (II).

No.	Pre-operative	1 m	3 ms	6 ms	2nd proceed
1	10	20	25	35	Revision
2	0	15	20	30	
3	5	30	30	45	
4	10	30	35	40	
5	20	35	35	30	V.P. arthroplasty arthrolysis
6	15	25	25	30	
7	0	30	40	45	
8	0	25	25	30	
9	0	15	20	30	
10	0	20	25	35	
5±5.8		24.5±6.9	27±6.3	36±6.6	

Table (8): Passive ROM in group (II).

No.	Pre-operative	1 m	3 ms	6 ms	2nd proceed
1	10	30	40	60	Revision
2	0	30	60	70	
3	5	40	50	60	
4	35	50	60	60	
5	50	50	50	60	V-P arthroplasty arthrolysis
6	40	40	45	60	
7	50	50	60	80	
8	0	30	40	60	
9	0	40	40	50	
10	0	50	70	80	
16±19.1		41±8.8	51.5±10.5	64±9.7	

Table (9): Effect of associated tendon injuries on postoperative active and passive ROM in group II.

Associated tendon injuries	No. of cases	Mean active ROM	Mean passive ROM
No tendon injury	4	38°	67°
Ext. tendon injuries	2	35°	70°
Flexor tendon injuries	2	37°	70°
Both tendon injuries	2	30°	60°

Table (10): Comparison between group (I) and (II) in terms of preoperative and postoperative active ROM.

Variable	Group I	Group II	p value	Significance
Preop. active ROM	8.9±7.8	5±5.8	0.34	Insignificant
Postop. active ROM	39.5±12.1	36±6.6	0.43	Insignificant

DISCUSSION

Post-traumatic arthritis leads to painful stiffness and/or instability of the proximal interphalangeal joint. It is usually a sequelae of intra-articular fractures of the P.I.P joint. Impairment and disability can be significant. With involvement of the index finger in particular, function is impaired by decrease pinch strength. Involvement of the middle, ring or little fingers, grip strength is more likely to be decreased [29].

The goal of treatment is to provide a painless, stable joint with a useful range of motion and acceptable appearance [30].

Arthrodesis has always been a reasonable option [15]. It provides pain relief, stability and correction of deformity in a single operation without the need for significant postoperative rehabilitation. On the other hand, joint arthrodesis sacrifices mobility and results in significant impairment of the hand [17]. It is also frequently accompanied by finger shortening and flexor tendon quadriga syndrome [2].

Although many arthroplasty techniques have been proposed, none have been universally successful [17]. These include resection arthroplasty, interposition arthroplasty. Vascularized joint transfer and prosthetic arthroplasty.

In terms of active ROM, the results of these arthroplasty procedures for P.I.P joint were similar (30°-40°) [31].

Prosthetic replacement has been popularized by Swanson [32,33]. Although good results were obtained in rheumatoid patients, the results were frequently less satisfactory in young patients with post-traumatic damaged P.I.P joint.

In prosthetic arthroplasty in the post-traumatic young patients many cases of infection, rupture of the implant, implant loosening, bone resorption and stiffness have been reported [34,35].

The ability of the perichondrium to provide a source of proliferative chondrogenic cells has been demonstrated by several authors [21,36,37,38].

This neochondrogenic potential of free perichondrial and perichondrio-costochondrial grafts makes it an attractive option for resurfacing of full thickness defects in articular cartilage as it is a living autologous tissue readily available and can produce more physiological results.

The first group consisted of 10 P.I.P joints in 10 patients were treated by perichondrio-

costochondral arthroplasty and the second group consisted of 10 P.I.P joints in 9 patients were treated with perichondrial arthroplasty.

Most of patients in both groups were satisfied from the overall postoperative results as they were pain free 90% in group I and 80% in group II.

These results of pain relief are in agreement of results reported by Katsaros et al., 1995 of perichondrio-costochondral arthroplasty, as 83% of cases were pain free and by Engkvist and Johansson, 1980 of perichondrial arthroplasty in which 75% of cases were pains free [25,39].

The postoperative results of both groups showed progressive improvement in the mean active and passive R.O.M. for 6 months postoperatively. After that there was no further improvement. This may be attributable to the short period of physiotherapy (2 months) or patient's reluctance in physiotherapy, as Ohlsen, 1978 reported an increase in the R.O.M. during a follow-up period of more than one year in the most of his cases with perichondrial arthroplasty [22].

The mean active and passive R.O.M obtained after 6 months in group I (perichondrio-costochondral arthroplasty) were 39.5° and 70° respectively. While the pre-operative active and passive R.O.M were 8.9° and 14.5° respectively, showing a highly significant improvement ($p = 0.00$).

The functional categorization of this group was good in 50% of cases, fair in 30% of cases and poor in 20% of cases. The mean active and passive R.O.M. obtained after 6 months in group II (perichondrial arthroplasty) were 36° and 64° respectively, while the preoperative mean active and passive R.O.M. were 5° and 16° respectively showing a highly significant improvement ($p = 0.00$).

The functional categorization of this group was 50% good, 30% fair and 20% poor. Patients with coexisting tendon injuries in both groups achieved less favorable results as regards the active R.O.M, even when concomitant tenolysis was performed. This is confirmed by the presence of a statistical significant difference in the mean active R.O.M between patients with and without tendon injuries. This is in agreement with what was reported by Michon et al., [40] and Hage et al., [41] as they noticed that poor results correlated with the condition of surrounding soft tissue. Even when satisfactory passive R.O.M. was obtained, the final active R.O.M. was limited by co-existing tendon injuries.

The patients of group I and II with pre-operative ankylosed joint R.O.M = 0° showed improvement in the postoperative mean active R.O.M. 32° and 31° respectively, while those patients did not improve in series of Engkvist and Johansson, of perichondrial arthroplasty [39].

The complications encountered in group I were one patient required revision (done early in the series) as the postoperative X-ray revealed narrow irregular joint space. Mostly, it is due to inadequate excision and contouring of joint surfaces during the primary procedure. The R.O.M was improved after revision. In the following cases technical improvement and refinement of contouring was established.

One patient developed peri-articular adhesions with improved R.O.M after arthrolysis. Two patients developed volar subluxation 20%. They had flexion contracture and they were subjected to capsuloligamentous release before arthroplasty and they ended up with arthrodesis.

Therefore, proper reinforcement or reconstruction of collateral ligament system and postoperative splinting may avoid this complication. In cases performed by Katsaros et al., [25] the only complication encountered is ulnar deviation which was present in 50% of cases probably due to radial collateral ligament laxity.

The complications encountered in group II were ankylosis in 2 cases 20% and persistent of pain 20%, while in series of Engkvist and Johansson, 1980 were ankylosis in 2 cases 29% and pain in one case 14% [40].

Perichondrial and perichondrio costochondral arthroplasties are considered to be biologic restoration of damaged articular surfaces.

Perichondrial arthroplasty requires the use of a silicone rubber joint spacer to prevent intra-articular adhesions (future joint space) [23,24] which needs a second stage for its removal. A technical point that not required in perichondrio-costochondral arthroplasty as the graft incorporates its own natural "in built" spacer [25].

Favorable results were obtained in this study with autograft joint resurfacing arthroplasty with both pain relief and improvement of ROM. Although those techniques perichondrial and perichondrio costochondral arthroplasty have previously been described, it is worthwhile to restate their value.

Better results can be obtained in cases with isolated joint involvement with intact tendons acting across the joint. So, tendon repair or tenolysis should be done after joint reconstruction to allow early postoperative rehabilitation. In addition patient co-operation and motivation is mandatory to obtain good results.

Perichondrio costochondral arthroplasty is useful management of post traumatic damaged P.I.P. Joint and other joints of the hand as an autogenously grafting technique especially in young, active co-operated highly motivated patients who need mobile painless and stable joints.

REFERENCES

- 1- Amadio P.C. and Murray P.M.: Arthroplasty of the proximal interphalangeal joint p. 267. In Morrey B.F. (ed): *Reconstructive surgery of the joints*. Churchill Livingstone, New York, 1996.
- 2- Foucher G., Lenoble E. and Smith D.: Free and island vascularized joint transfer for proximal interphalangeal reconstruction: A series of 27 cases. *J. Hand Surg.*, 19A: 8-15, 1994.
- 3- Dubousset J.: Anatomie fonctionnelle de l'appareil capsulo-ligamentaire des articulations des doigts (sauf le pouce). Monographie du G.E.M. Traumatismes osteo-articulaire de la main R. Vilain, edit. expansion scientifique française 1971.
- 4- Santos L.: Role du jeu agonistique. Dans L'analyse vectorielle de l'action musculaire pendant la flexion. Comptes rendus de l'Association des Anatomistes, 52: 1085-1087, 1968.
- 5- Armstrong C.G. and Mow V.C.: Friction, lubrication and wear of synovial joints in scientific foundation of orthopedics and traumatology. Edited by Owen R., Good-Fellow J. and Bullough P., Williams Heinemann, London pp. 223-232, 1980.
- 6- Buckwalter J.A. and Mow V.C.: Cartilage repair in osteoarthritis. In Moskowitz R.W., Howell D.S., Goldberg V.M., Mankin H.J. (eds) *Osteoarthritis: Diagnosis and Management* Ed 2 pp. 71-107, Philadelphia, W.B. Saunders, 1992.
- 7- Glimcher M.J., Koide S. and Shapiro F.: Cell origin and differentiation in the repair of full-thickness defects of articular cartilage. *J. Bone Joint Surg.*, 75A: 532-553, 1993.
- 8- Barcia M., Grande D.A., Mason J., et al.: Expression of human bone morphogenetic protein 7 in primary rabbit periosteal cells: potential utility in gene therapy for osteochondral repair. *Gene Therapy*, 5: 1098-1104, 1998.
- 9- Mankin H.J.: Current concepts review. The response of articular cartilage to mechanical injury. *J. Bone and Joint Surg.*, 64A: 460-466, 1982.
- 10- Boulas H.J.: Autograft replacement of small joint defects in the hand. *Clin. Orthop.* 327: 63-71, 1996.
- 11- Gilbert A. and Mathoulin C.H.: Replacement arthroplasty of the post-traumatic arthritic PIP joint: Review of the Literature. In Bruser P. and Gilbert A. (eds) *Finger bone and Joint injuries* pp. 295-302, Martin Dunitz Ltd, the Livery House, London, 1999.
- 12- Schenck R.R.: Advances in reconstruction of digital joints. *Clin. Plast. Surg.*, 24: 175-189, 1997.
- 13- Cesari B. and Alnot J.Y.: L'arthroplastie avec implant dans les arthroses interphalangiennes proximales. A propos d'une série de 27 cas avec un recul moyen de 5 ans, *La main* 2: 85-96, 1997.
- 14- Moberg E.: Arthrodesis of the finger joint. *Surg. Clin. North Am.*, 40: 465-470, 1960.
- 15- Tubiana R.: Arthrodesis of the fingers. In Tubiana R. (ed): *The hand* pp. 698-702 Vol. 2 W.B. Saunders Philadelphia, 1985.
- 16- Stern P.J. and Ho S.: Osteoarthritis of the proximal Interphalangeal Joint. *Hand Clin.*, 3: 405, 1987.
- 17- Ellis P.R. and Tsai T.M.: Management of the traumatized joint of the fingers. *Clin. Plast. Surg.*, 16: 457, 1989.
- 18- Sokolow C.: Anatomie et physiologie de L'interphalangienne proximale, cahiers d'enseignement de la société Française: de chirurgie de la main No. 7 Expansion scientifique Française: Paris: 107-116, 1995. Eaton R.G. and Mallerich M.M.: Volar arthroplasty of the proximal interphalangeal joint: A review of ten years' experience. *J. Hand Surg.*, 14: 71-87, 1980.
- 19- Eaton R.G. and Mallerich M.M.: Volar arthroplasty of the proximal interphalangeal joint: A review of ten years' experience. *J. Hand Surg.*, 14: 71-87, 1980.
- 20- Swanson A.B., Maupin B.K., Gajjar N.V. and Swanson G.D.: Flexible implant arthroplasty in the proximal interphalangeal joint of the hand. *J. Hand Surg.*, 10A: 796-805, 1985.
- 21- Engkvist O.: Reconstruction of patellar articular cartilage with free autologous perichondrial grafts: An experimental study in dogs. *Scand. J. Plast. Reconstr. Surg.*, 13: 361-369, 1979.
- 22- Ohlson L.: Cartilage regeneration from perichondrium. Experimental studies and clinical applications *plast. Reconstr. Surg.*, 62: 507-513, 1978.
- 23- Skoog T. and Johansson S.H.: The formation of articular cartilage from free perichondrial grafts. *Plast. Reconstr. Surg.*, 57: 1-6, 1976.
- 24- Sully L., Jackson I.T. and Sommerlad B.C.: Perichondrial grafting in rheumatoid metacarpophalangeal joints. *Hand*, 12; 2: 137-148, 1980.
- 25- Katsaros J., Milner R. and Marshall N.J.: Perichondrial arthroplasty incorporating a thin layer of costal cartilage. *J. Hand Surg.*, 20B: 137-142, 1995.
- 26- Johansson S.H. and Engkvist O.: Small joint reconstruction by perichondrial arthroplasty. *Clin. Plast. Surg.*, 8: 107, 1981.
- 27- Seradge H., Kutz J.A., Kleinert H.E., Lister G.D., Wolff T.W. and Atasoy E.: Perichondrial resurfacing arthroplasty in the hand; *J. Hand Surg.*, 9A: 6: 880-886, 1984.
- 28- Swanson A.B., Maupin B.K., Gajjar N.V. and Swanson G.D.: Flexible implant arthroplasty in the proximal interphalangeal joint of the hand, *J. Hand Surg.*, 10A: 796-805, 1985.

- 29- Leibovic S.J.: Internal fixation for small joint arthrodesis in the hand, *Hand Clin.*, 13: 601-13, 1997.
- 30- Thompson J.S.: Interphalangeal joint arthroplasties: In Bowers W.H. (ed): *The interphalangeal joints*. Churchill Livingstone, New York pp. 156, 1987.
- 31- Foucher G., Hoang P., Citron N., Merle M. and Dury M.: Joint reconstruction following trauma: Comparison of microsurgical transfer and conventional methods: A report of 61 cases. *J. Hand Surg.*, 11B: 388-93, 1986.
- 32- Swanson A.B.: Implant arthroplasty in the hand and upper extremity and its future, *Surg. Clin. N. Am.*, 61: 369, 1981.
- 33- Swanson A.B.: Flexible implant resection arthroplasty in the upper extremity: In tubiana R. (ed): *The hand*, Vol. 2, Philadelphia, WB. Saunders pp. 576, 1985.
- 34- Riggs S.A. and Cooney W.P.: Arthroplasty for the traumatized digital joint. *J. Hand Surg.*, 8: 215, 1983.
- 35- Conolly W.B. and Rath S.: Silastic implant arthroplasty for post-traumatic stiffness of the finger joints, *J. Hand Surg.*, 16b: 286-92, 1991.
- 36- Skoog T., Ohlsen L. and Sohn S.A.: The chondrogenic potential of the perichondrium. *Chir. Plast.*, 3: 19-103, 1975.
- 37- Engkvist O., Johansson S.H., Ohlsen L. and Skoog T.: Reconstruction of articular cartilage using autologous perichondrial grafts: A preliminary report. *Scand. J. Plast. Reconstr. Surg.*, 9: 203-206, 1975.
- 38- Engkvist O. and Wilander E.: Formation of cartilage from Rib perichondrium grafted to an articular defect in the femur condyle of the rabbit: *Scand J. Plast. Reconstr. Surg.*, 13: 371-376, 1979.
- 39- Engkvist O. and Johansson S.H.: Perichondrial arthroplasty: A clinical study of 26 patients. *Scand. J. Plast. Reconstr. Surg.*, 14: 71-87, 1980.
- 40- Michon J., Delagoutte J.P. and Jandeaux M.: Les implants en silastic de swanson en traumatologie de la main. *Ann. Chir. Plast.*, 19: 13-21, 1974.
- 41- Hage J.J., Yoe E.P.D., Zevering J.P. and de Groot P.J.M.: Proximal interphalangeal joint silicone arthroplasty for post-traumatic arthritis *J. Hand Surg.*, 24A: 73-77, 1999.